

## Turkish reliability of National Institutes of Health (NIH) Patient-Reported Outcomes Measurement Information System (PROMIS®) constipation scale

Ahmet Mamur<sup>1</sup>, Mehmet Kayhan<sup>2</sup>, Ugur Bilge<sup>3</sup>, Serkan Sungur<sup>3</sup>, Huseyin Balcioglu<sup>3</sup>, Ilhami Unluoglu<sup>3</sup>

<sup>1</sup>Eskisehir Public Health Directorate, Eskisehir, Turkey

<sup>2</sup>Eskisehir Tepebaşı Yeni Family Health Center, Eskisehir, Turkey

<sup>3</sup>Eskisehir Osmangazi University Faculty of Medicine Department of Family Medicine Eskisehir, Turkey

### Abstract

**Objective:** Scales can be used to determine the cause of constipation which is one of the gastrointestinal symptoms. In this study; our aim was to perform reliability study of the Turkish version of National Institutes of Health (NIH) Patient-Reported Outcomes Measurement Information System (PROMIS®) Constipation Scale.

**Material and Methods:** The Constipation scale was translated into Turkish by three researchers, and a consensus meeting was held after the translation process. The Turkish text on which the researchers agreed was translated into English by an independent professional translator. The researchers decided that there was no difference between the translated English text and the source text after they compared the two texts in terms of meaning and comprehensibility. As a result of this process, the researchers obtained the final version on which they agreed and the accuracy of which was proved by back translation.

**Results:** A total of 63 patients took part in this study. 32 of them (50.8%) were male, 31 of them (49.2%) were female. mean age of participants was 40,25±16,18 years. Mean questionnaire score was 11,38 ± 2,95. Cronbach's alpha coefficient was found to be 0.758 for 9 scale question.

**Discussion:** This study shows that Turkish version of PROMIS-Constipation scale is reliable. We believe that this scale may be used for the objective assessment of patients with constipation in clinical practice.

**Keywords:** NIH PROMIS GI Symptom Scales; Constipation; Turkish Reliability.

## INTRODUCTION

Constipation is not a diseases but a symptom that differs from person to person (1,2). The number of stools that varies from three in a day to once in three days is considered normal. In general, two or less defecation in a week is described as constipation. But the number of defecation alone is not a sufficient criterion. Amount of stool is also important as the number of defecation (2-4). Constipation is a very common gastrointestinal problem in the community (ranging from 2% to 28%) (2,5,6). According to studies conducted in Turkey, the rate of constipation varies between 22-40% (4). According to different studies, it is seen more frequently in women, children and elderly people (5,7,8).

In women; constipation rate increases with factors such as chronic immobility, inadequate fluid intake, inadequate/inappropriate diet, illnesses, psychological problems, and side effects of medications (7-9).

Scales can be used to find the cause of constipation. Scales were developed for objective assessment of symptoms. Constipation related scales generally question symptoms' frequency, severity and, in some cases, effect on quality of life within the last 7 days. (10).

In this study; our aim was to perform reliability study of the Turkish version of National Institutes of Health (NIH) Patient-Reported Outcomes Measurement Information System (PROMIS®) Constipation Scale.

## MATERIALS and METHODS

PROMIS, developed by NIH, provides patient-reported outcome measures for the assessment of diseases, including GI disorders. The PROMIS Constipation, one of the eight categories in the PROMIS GI item banks, is designed to measure the frequency, severity, impact and discomfort caused by main Constipation symptoms, based on the assumption that the complaints continue

Received: 31.01.2017

Accepted: 09.02.2017

### Corresponding Author

Ugur Bilge, Eskisehir Osmangazi University Faculty of Medicine Department of Family Medicine Eskisehir, Turkey

E-mail: [dr\\_ubilge@windowslive.com](mailto:dr_ubilge@windowslive.com)

for at least seven days. PROMIS Constipation scale has 9 items (10).

The questionnaire consisted of 9 questions, and in each question, the answers were scored from 0 to 4. The points for each question were summed. According to the scoring system in the original questionnaire, 0 point refers to not symptomatic, 1-3 points to least symptomatic, 4-7 points to mild symptomatic, 8-15 points to moderately symptomatic and 16 and more points to most symptomatic. The questionnaire was administered prospectively to patients equal and above 18 years that presented to Family Medicine outpatient clinic of Eskisehir Osmangazi University

**Translation process:** The Constipation scale was translated into Turkish by three researchers, and a consensus meeting was held after the translation process. The Turkish text on which the researchers agreed was translated into English by an independent professional translator. After the researchers compared the English text, a product of back translation, and the source text in terms of meaning and comprehensibility, they decided that there were no differences between the two texts. As a result of this process, the researchers obtained the final version on which they agreed and the accuracy of which was proved by back translation.

In order to test reliability of the questionnaire form, Cronbach's alpha coefficient was calculated for each

#### PROMIS- Constipation Scale (Turkish Reliability Version)

		Hiç	Çok az	Biraz	Sık	Çok fazla
<b>GI6</b> <b>4</b>	Sert veya topaklı gaita sizi ne kadar rahatsız etti?					
<b>GI6</b> <b>6</b>	Tuvaletinizi yapmaya çalışırken ne kadar zorluk hissettiniz?					
<b>GI6</b> <b>7</b>	Rahatsız edici barsak hareketleri sizi ne kadar rahatsız etti?	Hiçbir zaman	Bir gün	2-6 gün	Günde bir	Günde birden fazla
<b>GI6</b> <b>3</b>	Ne kadar sıklıkta sert veya yumrulu gayta yaptınız?	Hiçbir zaman	Nadiren	Bazen	Sık	Her zaman
<b>GI6</b> <b>5</b>	Tuvaletinizi yaparken ne kadar sıklıkta zorlandınız?					
<b>GI6</b> <b>8</b>	Tuvaletinizi yaparken rektum veya anüste ne kadar sıklıkta ağrı hissettiniz?					
<b>GI7</b> <b>2</b>	Barsak hareketiniz sonrasında ne sıklıkta boşaltımın bitmediği- yani bir miktar daha gaitanız kaldığını hissettiniz?					
<b>GI7</b> <b>4</b>	Gaytanızı çıkarmak için ne sıklıkta parmağınızı veya tuvalet kağıdını kullandınız?	Hiç değil	kötü	Çok az kötü	Biraz kötü	Oldukça kötü
<b>GI6</b> <b>9</b>	Tuvaletinizi yaparken rektum veya anüste (makatta) ağrınızı en kötü haliyle nasıl derecelendirirsiniz?					

Mean questionnaire score was 11,38 ± 2,95. The results indicate that 1 person was least symptomatic, 7 persons were mildly symptomatic, 49 persons were moderately symptomatic and 6 persons fell under the category of

question. In the case that Cronbach's alpha coefficient was minimum 0.70, it was considered that the questions were consistent with each other (11).

**Patient collection:** This study was conducted prospectively in the outpatient clinic of Family Medicine at Osmangazi University Faculty of Medicine between the dates of 15 June and 30 September 2016 after approval from ethical committee was received. The scale was administered to patients that above 18 years who presented to the outpatient clinic with constipation complaints lasting for at least one week. Patients below 18 years, above 18 years but have a cognitive disorder that prevents answering the questions and un volunteers were not included to the study. A consent form has been taken from all the patients who will participate in the study.

## RESULTS

A total of 63 patients took part in this study. 32 of them (50.8%) were male, 31 of them (49.2%) were female. Average age of participants was 40,25±16,18 years. 12 of patients (%19,0) were using NSAID (1 were diclofenac, 2 flurbiprofen, 2 metamizole, 1 etodolac, 5 dexketoprofen trometamol, 1 naproxen). 3 of patients were using PPI (2 were lansoprazole, 1 pantoprazole).

most symptomatic. The Cronbach's alpha coefficient of the scale was 0.758 for 9 questions. When evaluated separately for each question, the Cronbach's alpha coefficient was 0,700 at least and 0,768 at most for each

question. These results indicate that the Turkish version of the instrument was quite reliable. The distribution of Cronbach's alpha values by questions are provided in table 1.

**Table 1.** Distribution of Cronbach's Alpha values of questions

Questions	Cronbach's Alpha
Question-1	0.735
Question-2	0.712
Question-3	0.703
Question-4	0.761
Question-5	0.724
Question-6	0.700
Question-7	0.741
Question-8	0.760
Question-9	0.768

## DISCUSSION

In addition to invasive methods, scales are important methods to diagnose constipation. Scales were developed for objective assessment of symptoms (6).

NIH developed PROMIS at 2004 to provide patient-reported outcome measures for the assessment of diseases, including GI disorders. PROMIS tools are suitable for both traditional and electronic data collection methods. Reliable, valid and easily applicable PROMIS tools allow users to set collective language criteria for symptoms and determine clinical thresholds. Various users including patients, researchers and organizers can use these tools as guidelines for clinical decision making, clinical research and drug approval. Despite the development of more than 100 PRO related to GI symptoms, there is still a need to develop standardized, detailed, and electronic PRO measurement tools for clinical and research purposes that cover all GI symptoms (10).

The PROMIS-Constipation Scale is a short and easy-to-apply questionnaire that consists of 9 questions and allows us to evaluate each constipation symptom individually. The PROMIS Constipation, one of the eight categories in the PROMIS GI item banks, is designed to measure the frequency, severity, impact of and discomfort caused by main Constipation symptoms, based on the assumption that the complaints continue for at least seven days (10). The physician can question the complaints of constipation, and assess its severity

through this easy-to-apply questionnaire by taking a short amount of time.

This study shows that Turkish version of PROMIS-Constipation scale is reliable. We believe that this scale may be used for the objective assessment of patients with constipation in clinical practice.

## REFERENCES

1. Choung RS, Locke GR, Rey E, Schleck CD, Baum C, Zinsmeister AR, et al. Factors associated with persistent and nonpersistent chronic constipation, over 20 years. *Clin Gastroenterol Hepatol* 2012;10(5):494-500.
2. Papatheodoridis GV, Vlachogiannakos J, Karaitianos I, Karamanolis DG. A Greek survey of community prevalence and characteristics of constipation. *Eur J Gastroenterol Hepatol* 2010;22(3):354-60.
3. Kang DW, DiBaise JK, Ilhan ZE, Crowell MD, Rideout JR, Caporaso JG, et al. Gut microbial and short-chain fatty acid profiles in adults with chronic constipation before and after treatment with lubiprostone. *Anaerobe* 2015;9:33-41.
4. Ayaz S, Hisar F. The efficacy of education programme for preventing constipation in women. *Int J Nurs pract* 2014;20(3):275-82.
5. Schmidt FM, Santos VL. Prevalence of constipation in the general adult population: an integrative review. *J Wound Ostomy Continence Nurs* 2014;41(1):70-6.
6. Spiegel BM, Hays RD, Bolus R, Melmed GY, Chang L, Whitman C, et al. Corrigendum: development of the NIH patient-reported outcomes measurement information system (PROMIS) gastrointestinal symptom scales. *Am J Gastroenterol* 2015;110(4):608.
7. Soares NC, Ford AC. Prevalence of, and risk factors for, chronic idiopathic constipation in the community: systematic review and meta-analysis. *Am J Gastroenterol* 2011;106(9):1582-91.
8. Ribas Y, Saldaña E, Martí-Ragué J, Clavé P. Prevalence and pathophysiology of functional constipation among women in Catalonia, Spain. *Dis Colon Rectum* 2011;54(12):1560-9.
9. Locke GR, Pemberton JH, Phillips SF. AGA technical review on constipation. *Gastroenterology* 2000;119(6):1766-78.
10. Spiegel BM, Hays RD, Bolus R, Melmed GY, Chang L, Whitman C, et al. Development of the NIH patient-reported outcomes measurement information system (PROMIS) gastrointestinal symptom scales. *Am J Gastroenterol* 2014;109(11):1804-14.
11. Bland JM, Altman DG. Statistics notes: Cronbach's alpha. *BMJ* 1997;22;314(7080):572.

## Assessment of hip development in the early period in patients who underwent dega osteotomy due to developmental dysplasia of the hip

Baran Sarikaya<sup>1</sup>, Serkan Sipahioglu<sup>1</sup>, Zeynep Bekin Sarikaya<sup>2</sup>, Celal Bozkurt<sup>1</sup>, Ali Levent<sup>1</sup>, Metin Yapti<sup>1</sup>, Mehmet Akif Altay<sup>1</sup>, Ugur Erdem Isikan<sup>1</sup>

<sup>1</sup>Harran University Faculty of Medicine Department of Orthopaedics and Traumatology, Sanliurfa, Turkey

<sup>2</sup>Balikligol State Hospital Department of Radiology, Sanliurfa, Turkey

### Abstract

**Objective:** To examine hip development in a patient who underwent Dega osteotomy due to developmental dysplasia of the hip (DDH) by means of radiography.

**Materials and Methods:** Dega osteotomy was performed on 43 hips (7 were bilateral) of 36 patients with DDH. In preoperative and final follow-up; the acetabular index (AI), acetabular depth ratio (ADR) and Wiberg's center-edge angle (CEA) were measured in anteroposterior pelvic radiographs. Hips were classified in accordance with Tönnis classification system. Radiological findings were evaluated in accordance with Severin classification system. Avascular necrosis (AVN) of the hips were evaluated according to Kalamchi-MacEwen classification system.

**Results:** The mean age was 87 months (48-130 months), mean follow-up period was 30.5 months (15-62 months). The mean preoperative and final follow-up values of AI were 43° (28° to 60°) and 19° (6° to 34°), respectively. The mean preoperative and final follow-up values of ADR were detected as 14 (8 to 24) and 26 (18 to 42), respectively. The mean CEA was found as 38° (18° to 61°) at the final follow-up. Of the hips, 37 were Tönnis type 4 and 6 were Type 3. Totally 10 hips had AVN; of those, 6 were Type 1, 2 were Type 2 and 2 were Type 3 hips. According to Severin classification, 11 hips were Type 1a, 3 were Type 1b, 22 were Type 2a, 5 were Type 2b and 2 were Type 3.

**Conclusion:** In patients who underwent Dega osteotomy, hip development can be detected radiographically with satisfactory levels.

**Keywords:** Hip; Dysplasia; Osteotomy.

## INTRODUCTION

The aim in the treatment of developmental dysplasia of the hip (DDH) is to obtain a healthy hip joint development by maintaining a concentric reduction of the femoral head into the acetabulum (1). The consistency between femoral head and acetabulum and the continuity of it are required for development of hip joint. Hip dysplasia is generally treated with closed reduction procedure in children under the age of walking. At walking and later ages, pelvic osteotomy might be required together with open reduction procedure for reshaping or redirecting the dysplastic acetabulum to maintain a concentric hip reduction (2-4).

Dega technique was defined as a periacetabular transiliac osteotomy in DDH to perform especially on children at walking and later ages (5).

In the original Dega technique, incomplete osteotomy was done to the lateral aspect of ilium and osteotomy was completed by leaving an intact hinge posteriorly (intact posteromedial iliac cortex and sciatica notch). On the other hand, there are modifications involving anterior and posterior bicortical osteotomy and lateral middle part incomplete osteotomy (6).

Dega osteotomy can be performed when triradiate cartilage is opened or closed; however, there were studies asserting that osteotomy must be performed before the closure of triradiate cartilage to enable hinge-like function of the triradiate cartilage (7). In the present study, we aimed to investigate the radiographic results of hip development in patients who underwent Dega osteotomy.

## MATERIALS and METHODS

In our study, 43 hips of 36 patients who were admitted to Harran University, Medical Faculty Hospital between the years of 2010 and 2016 and underwent Dega osteotomy due to DDH were retrospectively evaluated. Prior to the surgery, detailed information was given to the patients' relatives regarding the surgical procedure and its possible outcomes and their consents were taken. The study was conducted in the direction of

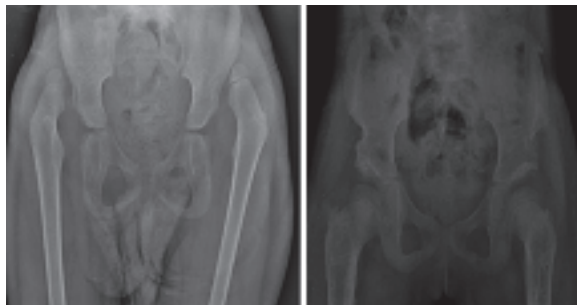
Received: 01.02.2017

Accepted: 13.02.2017

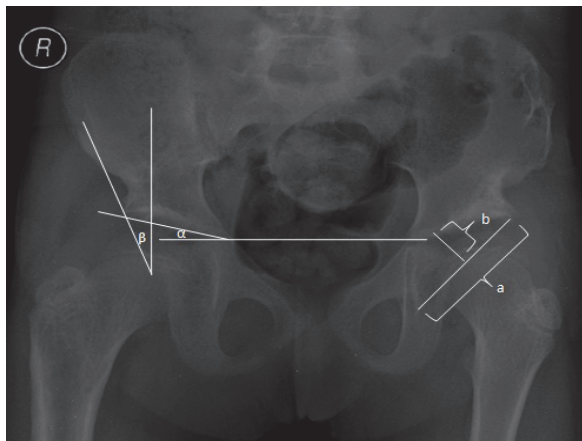
### Corresponding Author

Baran Sarikaya, Harran University School of Medicine  
Department of Orthopaedics and Traumatology,  
Sanliurfa, Turkey  
E-mail: [baransarikaya@yahoo.com](mailto:baransarikaya@yahoo.com)

Helsinki principles. Anteroposterior and frog-leg radiographs were evaluated in the preoperative and at the final follow-ups of the patients (figure 1). Acetabular index (AI), acetabular depth ratio (ADR) (8) and Wiberg's center-edge angle (CEA) (9) were assessed by means of radiographic approach. ADR was calculated by acetabular depth/acetabular width x 100. Acetabular width is measured as the distance between the lateral margin of the sourcil and the most inferior aspect of the acetabular teardrop and acetabular depth is defined as the perpendicular distance between the halfway point of the acetabular width and the roof of the acetabulum (10) (Figure 2).



**Figure 1 a-b.** Development of hip joint, prior to Dega osteotomy and at the final follow-up, in 63 month-old female patient (a- preoperative image b- 24-month follow-up roentgenography)



**Figure 2.** Radiological measurements in a patient with bilateral Dega osteotomy. ( $\alpha$ : Acetabular index angle,  $\beta$ : Center-edge angle, acetabular depth ratio:  $b/a \times 100$ ) Dysplastic hips were graded according to the Tönnis Classification System (11). Avascular necrosis (AVN) was evaluated according to Kalamchi-MacEwen Classification System (12). According to these findings, Grade 1; variations in the center of femoral ossification (no or Grade-I osteonecrosis), Grade 2; lateral physeal injury, Grade 3; central physeal injury, Grade 4; total injury in femoral physis. Radiographic findings of the operated hips were classified according to Severin Classification System (13,14). According to Severin Classification, hips in Group 1 and Group 2 were evaluated as satisfactory and hips in Group 3 and Group 4 were evaluated as unsatisfactory (table 1).

**Table 1.** Severin Classification

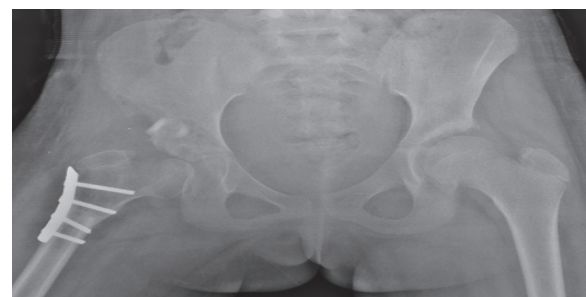
Group	Radiography	Age	CEA
<b>1. Normal</b>			
1a		6-13	>19°
		≥ 14	>25°
1b		6-13	15°-19°
		≥ 14	20°-25°
<b>2. Proximal femur, mild-medium deformation of acetabulum</b>			
2a		6-13	>19°
		≥ 14	>25°
2b		6-13	15°-19°
		≥ 14	20°-25°
<b>3 Dysplasia without subluxation, Shenton's line is intact</b>			
		6-13	<15°
		≥14	<20°
<b>4 Subluxation, Shenton's line is broken</b>			
4a			≥0°
4b			<0°
<b>5 Femoral head and false acetabulum form a joint</b>			
<b>6 Redislocation</b>			

(CEA: Center-edge angle)

### Surgical Technique

In all patients, adductor tenotomy was initially performed on dysplastic side. Tenotomy to iliopsoas and open reduction was done to all hips. Ilioinguinal (bikini) incision was performed for pelvic osteotomy. Dega osteotomy was performed by incomplete semicircular transiliac osteotomy, starting from just above the anterior inferior iliac spine and 1 cm superior to the acetabulum rim towards the sciatic notch in the posterior (6). Subtrochanteric femoral shortening and derotation was done through a separate lateral incision. The amount of shortening was determined preoperatively by measuring the distance from the inferior margin of the femoral head and the floor of the acetabulum.

Following the maintenance of derotation after femoral shortening, dynamic compression plate was used for femur detection. We applied a resected femoral segment for the pelvic osteotomy line as a graft. Pelvipedal plaster was applied for postoperative 6 weeks in all patients. And then, patients were closely followed-up during orthosis-therapy (Figure 3).



**Figure 3.** The view of the osteotomy line and autogen graft in a patient with Dega osteotomy. Early postoperative radiography

**Statistical Analysis**

The statistical relationship between preoperative and final follow-up radiographic findings of the patients was evaluated. According to this evaluation, data distribution was determined by Kolmogorov-Smirnov test. The data with normal distribution was evaluated by paired t-test. The data that were not normally distributed were evaluated by using Wilcoxon test. Pearson correlation test was performed for correlation analysis. Statistical tests were done by using IBM SPSS 22.0 version (IBM Corporation, Armonk, NY, USA) and  $p < 0.05$  was accepted as statistically significant.

**RESULTS**

Dega osteotomy was performed on 43 hips (7 were bilateral) of 36 patients in total. Of the patients, 6 were male and 30 were female. The mean age was 87 months

(range, 48-130 months), the mean follow-up period was 30.5 months (range, 15-62 months). While the mean preoperative AI angle was 43° (range, 28° to 60°), it was 19° (range, 6° to 34°) at the final follow-up. The mean variation was 23° (range, 9° to 36°) in AI. While the mean preoperative ADR value was 14 (range, 8 to 24), it was 26 (range, 18 to 42) at the final follow-up. When preoperative and final follow-up AI and ADR parameters were compared to each other, a statistically significant difference was detected in both parameters ( $p < 0.001$ ). The mean CEA was detected as 38° (range, 18° to 61°). When the correlation between radiographic parameters were investigated, a correlation was detected between the decreased AI values and increased CE angles ( $p = 0.002$ ). There was a correlation between age and CE angle ( $p = 0.036$ ) (table 2).

**Table 2.** Radiographic assessment of hips in patients who underwent Dega osteotomy

AI		ADI		CEA	Kalamchi-MacEwen Classification			Tönnis Classification		Severin Classification				
Preoperative	Final follow-up	Preoperative	Final follow-up	Final follow-up	Type 1	Type 2	Type 3	Type 3	Type 4	Type 1a	Type 1b	Type 2a	Type 2b	Type 3
43° (28°-60°)	19° (6°-34°)	14 (8-24)	26 (18-42)	38° (18°-61°)	6 hips	2 hips	2 hips	6 hips	37 hips	11	3	22	5	2

(AI: Acetabular index, ADR: Acetabular depth ratio, CEA: Center-edge angle)

Of the hips, 37 were Tönnis Type 4 and 6 were Type 3. According to Kalamchi-MacEwen classification, totally 10 hips had AVN; of those, 6 were Type 1, 2 were Type 2 and 2 were Type 3 hips. All hips with AVN were Tönnis Type 4.

According to Severin Classification, 11 hips were Type 1a, 3 were Type 1b, 22 were Type 2a, 5 were Type 2b and 2 were Type 3. Therefore, only the radiographic outcomes of 2 hips were unsatisfactory in terms of dysplasia. These 2 hips were Type 3 according to Kalamchi-MacEwen Classification. The mean follow-up period was 30.5 months and neither subluxation nor redislocation was detected in the hips.

**DISCUSSION**

Whatever the age group is, the aim of DDH is to obtain a healthy hip joint development by enabling a consistency between femoral head and acetabulum (15). Thus, Dega osteotomy has been defined for this purpose and it is one of the pelvic osteotomies that can be applied on DDH patients at the age of walking (2,16). Pelvic osteotomy, femoral shortening and open reduction are basic approaches that are applied to children at the age of walking for DDH treatment. Wenger recommended primary femoral shortening, anterior open reduction and capsulography (with or without pelvic osteotomy) in children older than 3 years (17). Dislocated hips with DDH must be reduced as early as possible. The anatomical structure, such as iliopsoas, adductor muscles, lateral capsule and the reflected head of rectus femoris, might cause deformations in femoral head and acetabulum. Muscle tension might result in deformities including coxa valga and antetortia in dislocated proximal femur (18).

In the original technique of Dega osteotomy, osteotomy was not performed on the posterior sciatic notch (5). However, the anterior and posterior parts of the iliac bone were osteotomized bicortically by means of the modified techniques in the later years (6,19). Thus, acetabulum was more covered to femoral head. We preferred modified Dega osteotomy in our cases as well. In our study, the mean final follow-up angle of AI was 19° and it was decreased by 23° in average in comparison to preoperative period. According to the relevant studies in the literature, Ming-Hua et al. and Kim et al. found a regression in AI angles from 38° to 20.8° and from 39° to 15°, respectively (20). When we compared to other certain studies, we detected similar and satisfactory outcomes in between AI angles (7,21).

Just as in Pemberton osteotomy, Dega osteotomy is an acetabular reconstruction procedure reshaping the acetabulum (5,22). Morphological variations might be seen in the acetabulum after both procedures. Thus, they might result in alterations in the acetabular volume. The effects of Dega and Pemberton osteotomies on the acetabular volume are contradictive (23), and it has been reported in MR and CT studies that Dega osteotomy cause an increase in acetabular volume (24,25). The radiographic alterations in ADR might give us an idea regarding the acetabular volume. In our study, the final follow-up radiographic outcomes of ADR were increased in comparison to preoperative period. This variation in ADR is also the indicator of increased level of coverage between acetabulum and femoral head.

We are using femoral graft in iliac osteotomy in all patients who underwent femoral shortening. Therefore, we do not result in an additional morbidity by obtaining iliac graft. In another case series, we compared iliac crest

graft morbidity with femoral graft morbidity in patients that we performed Pemberton osteotomy. We detected lower morbidity in patients in whom we performed femoral grafting (26).

Wiberg's CEA is a radiographic parameter that further comes to the forefront, especially for the presentation of relationship between acetabulum and femoral head. In our study, an increase in CEA was detected that was correlated with the decrease in AI. An increase was also detected in CEA by means of reduced acetabular dysplasia and normal development of well-covered femoral head. Ming-Hua et al. found CEA as 29° after the high osteotomy cut Dega procedure (20). In another study, it was detected as 31° in average (27). In the present study, the mean CEA was 38°. We might conclude that we obtained a satisfactory femoral head coverage between femoral head and acetabulum.

The remodeling capacity of acetabulum depends on the age. In the literature, there is not a particular consensus on the age limit. However, the remodeling capacity was stated to be decreased towards the age of 6 (20, 28). Ponseti revealed that the acetabulum has been developed and acetabular depth has been increased by means of interstitial growth in the acetabular cartilage, the appositional growth at the periphery of this cartilage and periosteal new-bone formation at the acetabular margin (29). Owing to this growth capacity, patient should be followed-up until the maturation of skeletal system. When the patients with unilateral dysplasia were followed-up closely, the possibility of contralateral dysplasia formation has been shown in these patients (30). The development of AI value was shown to be gradually decreased in a hip with reduction and without subluxation in contrast to the discontinuation of AI development within 2 to 3 years in a hip without reduction (31). Assessment of the acetabular development, AI is not adequate by itself. The CEA, especially as child grow older (after 5 years of age), is a radiographic criteria that has to be evaluated together with AI. According to Severin Classification, it has been shown that acetabular development will be stopped after 4 to 5 years in the presence of grade 3 and grade 4 hips; however, it might take several years in the presence of grade 1 and grade 2 hips (32). In our study, we detected type 3 hip only in 2 hips according to Severin Classification. Despite of satisfactory outcomes regarding the AI values in these hips with follow-up periods of 19 and 26 months, respectively, net data will be obtained by longer follow-up periods about hip development. In the remaining 43 hips that underwent Dega osteotomy, we acquired satisfactory outcomes according to the Severe Classification. In a similar study including 43 hips that underwent Dega osteotomy and followed-up for 2 years in average, unsatisfactory results were obtained in the radiographic parameters of only 5 patients (33). In another study consisting of 58 hips, the outcomes were not satisfactory in accordance with the Severin Classification in 16 hips (34). Therefore, when we examined the similar studies in the literature and considered that the outcomes were unsatisfactory only in 2 hips, it might be concluded that we obtained satisfactory results according to Severin Classification

indicating the final radiographic condition of the treated hips.

AVN is one of the complications in the DDH treatment. Kalamchi-MacEwen is frequently used in the classification of AVN. The symptoms of AVN might arise even months or years after the treatment. The involvement of lateral growth plate of femoral head, especially in type 2 AVN, emerges at the age of 10 years in average (35). In a study performed by Kim et al., AVN was detected only in 2 hips and it was detected in 6 patients in another study (17,36). In our study, the symptoms of AVN were confirmed totally in 10 hips; however, of those, 6 were type 1. There are opinions indicating that type 1 AVN is not an AVN entirely and it is the indicator of developmental remodeling in treated hip (12). In this context, we might remark that the ratio of AVN in our patient group shows similarity to those in the literature.

In conclusion, we obtained satisfactory radiographic outcomes at hip joint following Dega osteotomy. As we revealed in our study, there was a dramatic and radiographic developmental process in the hip joint at the early period following a regular surgical treatment that was performed considerably to the soft tissue and enabled a consistency between femoral head and acetabular. In order to make a healthier assessment, long-term outcomes should also be addressed.

## REFERENCES

1. Issin A, Oner A, Kockara N, Camurcu Y. Comparison of open reduction alone and open reduction plus Dega osteotomy in developmental dysplasia of the hip. *J Pediatr Orthop B* 2016;25(1):1-6.
2. Carlioz H. [Pelvic osteotomies in children and adolescents]. *Acta Orthop Belg* 2000;66(4):321-8.
3. Krieg AH, Hefti F. [Acetabuloplasty - The Dega and Pemberton technique]. *Orthopade* 2016;45(8):653-8.
4. Harris NH, Lloyd-Roberts GC, Gallien R. Acetabular development in congenital dislocation of the hip. With special reference to the indications for acetabuloplasty and pelvic or femoral realignment osteotomy. *J Bone Joint Surg Br.* 1975;57(1):46-52.
5. Dega W. [Selection of surgical methods in the treatment of congenital dislocation of the hip in children]. *Chir Narzadow Ruchu Ortop Pol.* 1969;34(3):357-66.
6. Mubarak SJ, Valencia FG, Wenger DR. One-stage correction of the spastic dislocated hip: use of pericapsular acetabuloplasty to improve coverage. *J Bone Joint Surg (Am)* 1992;74(9):1347-57.
7. Grudziak JS, Ward WT. Dega osteotomy for the treatment of congenital dysplasia of the hip. *J Bone Joint Surg Am.* 2001;83-A(6):845-54.
8. Heyman CH, Herndon CH. Legg-Perthes disease; a method for the measurement of the roentgenographic result. *J Bone Joint Surg Am* 1950;32 A(4):767-78.
9. Wiberg G. Studies on dysplastic acetabula and congenital subluxation of the hip joint with special reference to the complication of osteoarthritis. *Acta Chir Scand.* 1939;83 (Suppl 58):33-8.
10. Novais EN, Pan Z, Autruong PT, Meyers ML, Chang FM. Normal Percentile Reference Curves and Correlation of Acetabular Index and Acetabular Depth Ratio in Children. *J Pediatr Orthop* 2016.

11. Tönnis D. Congenital dysplasia and dislocation of the hip in children and adults. Springer-Verla 1987:100-47.
12. Kalamchi A, MacEwen GD. Avascular necrosis following treatment of congenital dislocation of the hip. *J Bone Joint Surg Am* 1980;62(6):876-88.
13. Severin E. Contribution to the knowledge of congenital dislocation of the hip joint. Late results of closed reduction and arthrographic studies of recent cases. *Acta Chir Scand* 1941;84(Suppl 63);84:1-142.
14. Omeroglu H. Geliçimsel Kalça Displazisinde Tedavi Sonuçlarının Radyolojik Değerlendirmesi.
15. Al-Ghamdi A, Rendon JS, Al-Faya F, Saran N, Benaroch T, Hamdy RC. Dega osteotomy for the correction of acetabular dysplasia of the hip: a radiographic review of 21 cases. *J Pediatr Orthop* 2012;32(2):113-20.
16. Aksoy C, Yilgor C, Demirkiran G, Caglar O. Evaluation of acetabular development after Dega acetabuloplasty in developmental dysplasia of the hip. *J Pediatr Orthop B* 2013;22(2):91-5.
17. Wenger DR. Congenital hip dislocation: techniques for primary open reduction including femoral shortening. *Instr Course Lect* 1989;38:343-54.
18. Braatz F, Staude D, Klotz MC, Wolf SI, Dreher T, Lakemeier S. Hip-joint congruity after Dega osteotomy in patients with cerebral palsy: long-term results. *Int Orthop* 2016;40(8):1663-8.
19. McNerney NP, Mubarak SJ, Wenger DR. One-stage correction of the dysplastic hip in cerebral palsy with the San Diego acetabuloplasty: results and complications in 104 hips. *J Pediatr Orthop* 2000;20(1):93-103.
20. Ming-Hua D, Rui-Jiang X, Wen-Chao L. The high osteotomy cut of Dega procedure for developmental dysplasia of the hip in children under 6 years of age. *Orthopade* 2016;45(12):1050-7.
21. Karlen JW, Skaggs DL, Ramachandran M, Kay RM. The Dega osteotomy: a versatile osteotomy in the treatment of developmental and neuromuscular hip pathology. *J Pediatr Orthop* 2009;29(7):676-82.
22. Pemberton PA. Pericapsular Osteotomy of the Ilium for Treatment of Congenital Subluxation and Dislocation of the Hip. *J Bone Joint Surg Am* 1965;47:65-86.
23. Weinstein S. Developmental hip dysplasia and dislocation. In: Morrissy RT, Weinstein SL, eds. *Lovell and Winter's Pediatric Orthopaedics*. Sixth edition. Philadelphia:Lippincott Williams&Wilkins;2006.p.987-1037.
24. Chung CY, Choi IH, Cho TJ, Yoo WJ, Lee SH, Park MS. Morphometric changes in the acetabulum after Dega osteotomy in patients with cerebral palsy. *J Bone Joint Surg Br* 2008;90(1):88-91.
25. Ozgur AF, Aksoy MC, Kandemir U, Karcaaltncaba M, Aydingoz U, Yazici M. et al. Does Dega osteotomy increase acetabular volume in developmental dysplasia of the hip? *J Pediatr Orthop B* 2006;15(2):83-6.
26. Ertürk C, Altay MA, İşikan UE. Femoral segment graft is a suitable alternative to stabilize pelvic osteotomies in developmental dysplasia of the hip: a comparative study. *J Pediatr Orthop B* 2012;21(3):200-5.
27. Akgul T, Bora Goksan S, Bilgili F, Valiyev N, Hurmeydan OM. Radiological results of modified Dega osteotomy in Tönnis grade 3 and 4 developmental dysplasia of the hip. *J Pediatr Orthop B* 2014;23(4):333-8.
28. Kobayashi D, Satsuma S, Kuroda R, Kurosaka M. Acetabular development in the contralateral hip in patients with unilateral developmental dysplasia of the hip. *J Bone Joint Surg Am*. 2010;92(6):1390-7.
29. Ponseti IV. Growth and development of the acetabulum in the normal child. Anatomical, histological, and roentgenographic studies. *J Bone Joint Surg Am* 1978;60(5):575-85.
30. Song FS, McCarthy JJ, MacEwan GD, Fuchs KE, Dulka SE. The incidence of occult dysplasia of the contralateral hip in children with unilateral hip dysplasia. *J Pediatr Orthop* 2008;28(2):173-6.
31. Zionts LE, MacEwen GD. Treatment of congenital dislocation of the hip in children between the ages of one and three years. *J Bone Joint Surg Am* 1986;68(6):829-46.
32. Albinana J, Dolan LA, Spratt KF, Morcuende J, Meyer MD, Weinstein SL. Acetabular dysplasia after treatment for developmental dysplasia of the hip. Implications for secondary procedures. *J Bone Joint Surg Br*. 2004;86(6):876-86.
33. Lopez-Carreno E, Carillo H, Gutierrez M. Dega versus Salter osteotomy for the treatment of developmental dysplasia of the hip. *J Pediatr Orthop B* 2008;17(5):213-21.
34. El-Sayed MM, Hegazy M, Abdelatif NM, ElGebeily MA, ElSobky T, Nader S. Dega osteotomy for the management of developmental dysplasia of the hip in children aged 2-8 years: results of 58 consecutive osteotomies after 13-25 years of follow-up. *J Child Orthop* 2015;9(3):191-8.
35. Kim HW, Morcuende JA, Dolan LA, Weinstein S. Acetabular development in developmental dysplasia of the hip complicated by lateral growth disturbance of the capital femoral epiphysis. *J Bone Joint Surg Am* 2000;82-A(12):1692-700.
36. Kim HT, Jang JH, Ahn JM, Lee JS, Kang DJ. Early results of one-stage correction for hip instability in cerebral palsy. *Clin Orthop Surg* 2012;4(2):139-48.